

Research Article

Sono-Guided Versus Conventional Dilation and Curettage in El-Minia University Hospital: A Randomized Controlled Trial

Hany H. kamel*

*Department of Obstetric and Gynecology, Faculty of Medicine, El-Minia University. Egypt.

Abstract

Background: Dilation and Curettage (D&C) is one of the most commonly performed gynecological procedures. Basically, the procedure has diagnostic and therapeutic indications for a diverse gynecological disorders that might affect the dynamic female reproductive organ; the uterus. Although it is used to be an easy intervention, short and long term complications were, and will be, reported. To optimize the benefits and minimize the risks inherent to the conventional procedure, continuous ultrasound guidance was tried during dilation and curettage. The aim of the work is to examine whether sono-guided dilation and curettage is effective and safer than the conventional procedure. **Methods:** A randomized controlled trial. El-Minia University Hospital, El-Minia, Egypt. patients scheduled for dilation and curettage for first trimester missed abortion recruited among the attendants of the Obstetrics and Gynecology Clinics since January 2021 through February 2022. Women were randomized to have dilation and curettage with or without continuous ultrasound monitoring. The primary outcome measures were surgical short-term complications (anesthetic complication, blood loss, cervical trauma, uterine perforation, need for laparoscopy and/or laparotomy, repeat uterine evacuation, and infection). The secondary outcomes were the procedure time and convalescence time. **Results:** A total of 200 patients (100 in each arm of the trial) participated in the study. Baseline characteristics were similar in both groups Overall significant complications occurred in 36 out of 200 cases (18%) with complete follow up information. Study group had a complication rate of 4.4% (11/250) in comparison to 10% (20/200) in the control (RR 0.21, 95% CI 0.07-0.60). Intra-operative ultrasound use also had a statistically significant beneficial effect in reducing the blood loss, procedure time, and convalescence time. **Conclusion:** Sono-guided dilation and curettage is more safe and effective than the conventionally performed procedure.

Keywords: Dilation and Curettage, Ultrasound, Randomized controlled trial

Introduction

Diagnostic dilation and curettage was originally intended to detect intrauterine endometrial abnormalities and assist in the management of abnormal bleeding⁽¹⁾.

Newer techniques are available to assess the uterine cavity and endometrial finding however, dilation and curettage still has a role in centers where advanced technology is not available or when other diagnostic modalities are unsuccessful⁽¹⁾.

Diagnostic dilation and curettage is typically employed to assess endometrial

histology⁽¹⁾. Fractional dilation and curettage also includes assessment of the endocervix and biopsy of the ectocervix and transformation zone.⁽²⁾

Dilation and curettage has a diagnostic indications as irregular bleeding, menorrhagia, suspected malignant or premalignant condition, retained material in the endometrial cavity, evaluation of intracavitary findings from imaging procedures (abnormal endometrial appearance due to suspected polyps or fibroids), evaluation and removal of retained fluids or tissues from the endometrial cavity⁽³⁾.

Also, D&C has therapeutic indications as Removal of retained products of conception (eg, incomplete abortion, missed abortion, septic abortion, induced pregnancy termination), Suction procedures for management of uterine hemorrhage, treatment and evaluation of gestational trophoblastic disease, hemorrhage unresponsive to hormone therapy, and in conjunction with endometrial ablation for histologic evaluation of the endometrium¹.

Traditionally, dilation and curettage has been performed in a blind fashion since doctors do not see the inside of the woman's uterus when performing this D&C surgery it is often labeled a "blind surgery". The scraping and/or suctioning inside the uterus is performed by viewing only what is external to it: the doctor's own hands, the patient's vagina and cervix and a portion of the instruments. This can lead to removing too little (leaving behind retained contents which may lead to needing another procedure) and can also lead to going too deeply, (such as damaging the basal layer of endometrium or removing superficial myometrium--uterine muscle). The procedure can be performed under ultrasound guidance^(v) or in conjunction with visualization of the uterine cavity by a hysteroscope^(A).

Being a blind technique it has many complication involving cervical laceration, uterine perforation, overcurettage with intrauterine adhesion and liability for post procedure bleeding and infection¹.

According to Egyptian Ministry Of Health (2008); estimated MMR for Upper Egypt Governorates was 09 per 100,000 births. One of the avoidable maternal mortality causes is unsafe abortion that represents 1.7% of the reasons of death¹.

Dilation and curettage is a widely practiced procedure by gynecologists of varying levels of expertise, so in our locality in Upper Egypt, the curette is used with the greatest freedom applying the most accepted rule of conduct "when in doubt curette". Some dangers related to D&C procedure were silently buried- sometimes underground.

In this study which is a randomized trial we are comparing blind D&C procedure with ultrasound guided D&C for first trimester missed abortion.

Subjects and Methods

A total of 000 women attending the department of obstetrics and gynecology, Minia university hospital, they were invited to participate in this study during the period between January 2011 to February 2012.

An informed consent was taken and the trial was approved by the ethical committee in the department. The patients admitted to the department to do D&C operation for Missed first trimester abortion.

Exclusion criteria:

- previously scarred uterus
- bleeding tendency
- history of previous uterine perforation
- associated uterine pathology as fibroid or malformed uterus

The patients were randomly divided by means of closed envelopes into two groups:
* Study group involving 200 women undergo D&C operation under ultrasound guide
* The control group involving 200 women undergo D&C in traditional blind fashion.

For all patients, history was taken, general, abdominal and local examination done. Ultrasound was done for all in the clinic evaluating the size of the uterus, direction, recording intrauterine findings and Registered in own patients files.

Evacuation of the bladder was advised before the procedure. After positioning the patient appropriately on the operating table, bimanual pelvic examination was performed under anesthesia to assess the axis and the size of the uterus, then the cervix was grasped using volselum forceps .then the cervix is being dilated using Hegar dilators up to the appropriate one which facilitate the passage of the curette.

The uterine cavity was evacuated by the curette till complete evacuation done. The women in the study group had a preliminary scan to assess the size and axis of the uterus,

position and the operation site. The abdominal transducer was used to obtain a longitudinal image of the uterus and cervix and provide the surgeon with a proper visualization of the uterine cavity, cervical canal and any instruments passed into the uterus.

The progress of the operation was continuously monitored only under direct ultrasound guidance till complete evacuation.

Patients remained in the hospital for 12 hours post-operatively where follow up charts including pulse, blood pressure, and post-operative bleeding were assessed and recorded.

Also analgesics and antibiotics prescribed for all patients. Before discharge, pelvic ultrasound was done to confirm complete evacuation and exclude any pelvic collection.

The primary outcomes were intra-operative and short-term complications. These included anesthetic complication, hemorrhage (measured blood loss > 500 ml where the blood is collected in a calibrated diaper). Cervical trauma (cervical laceration requiring suture or false passage), uterine perforation, need for laparoscopy and/or laparotomy, incomplete evacuation requiring repeat evacuation, and infection.

The infection was defined as a clinical need for antibiotic excluding prophylactic dose or a temperature of 38°C on at least two occasions, or endometritis suspected by abnormal vaginal discharge and pelvic tenderness.

The secondary outcomes were intra-operative blood loss, procedure time (the time required to complete the procedure from the start of cervical dilatation to the removal of the Volsellum from the cervix).

The patients were invited to come back to the hospital one week later to reassess their data as, pain, fever, bleeding, required cases for readmission or any other complications.

The data were analyzed using the Statistical Package for Social Sciences for Windows Version 9.0 (SPSS Inc., Chicago, IL, USA). All tests were performed two-sided and the differences were considered statistically significant if the P-value was < 0.05 .

Results

Sociodemographic criteria were similar in both groups with insignificant differences as shown in table 1. total number of cases was 500 patients, all of them met our inclusion criteria and continued all through the study stages which ended one week post operatively.

Overall significant complications occurred in 36 out of 500 cases (7.2%) with complete follow up information. Study group had a complication rate of 4.4% (11/250) in comparison to 10% (25/250) in the control (RR 0.21, 95% CI 0.07-0.65). The complications varied from anesthetic complications, cervical laceration, up to perforation and heavy bleeding more than 500 cc of blood (table 2).

Most of these complications was in the control group with 4 cases of perforation in this group versus one case only in the study group (p value 0.003).

The intraoperative and short-term complications observed are summarized in Table 3. There were no visceral damages and none of the patients required blood transfusion or additional surgery, such as laparoscopy and/or laparotomy.

The operative time was shorter in the study group (12 ± 2.7 min) than the control group (17 ± 1.8) with significant p value (0.04).

The ultrasound guided procedure was satisfactory for the expert surgeon to complete the procedure safely under vision. The secondary outcomes and other information obtained following discharge from the hospital are summarized in Table 3. There was also a positive correlation between the procedure time and the blood loss at the operation (Pearson $r = 0.4$, $P < 0.001$).

Table 1: Socio-demographic criteria of both groups

Variable	Study group (n.200)	Control group (n.200)	p.value
Age	23±1.2	23±1.6	0.6
BMI	18±1.4	18±1.3	0.4
Gestational age (weeks)	10±1.0	9±1.8	0.8
Recurrent D&C	28	31	0.9

Table 2: Intra-operative and early postoperative complications

complications	Study group (n.200)	Control group (n.200)	p.value
Anaesthetic complications	2	3	0.6
Cervical trauma needing suturing	1	2	0.2
Heavy bleeding ≥ 500 cc	0	1	0.02
Perforation	1	4	0.04
infection	3	0	0.4
Need to repeat the operation	0	0	0.03
Pain(need more analgesia)	4	0	0.7

Table 3: Secondary outcome measures

Variables	Study group (n.200)	Control group (n.200)	p.value
Procedure time (minutes)	12±2.6	17±1.8	0.04
Intra-operative blood loss (ml)	90±3.6	100±2.4	0.03
Postoperative bleeding days	3±1.0	4±2.3	0.01

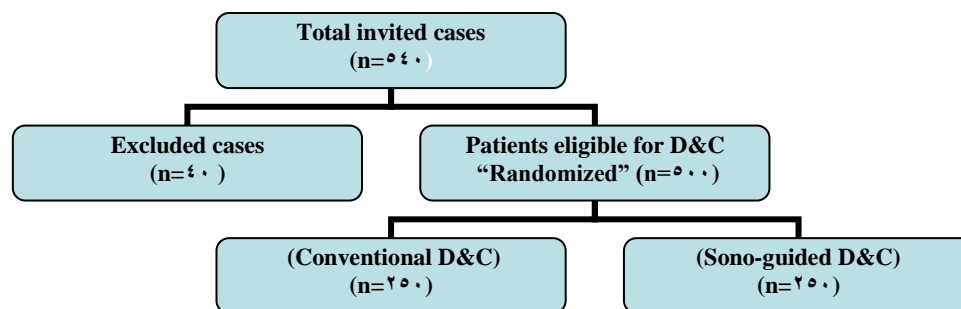


Fig. I illustrates study design

Discussion

This study which a randomized controlled one showing a beneficial effect of doing D&C operation under vision by reducing the possible risk of complications.

The skill and experience of the surgeon are important determinants of the safety of the operation, so a single experienced gynecologist performed all the operations in this study minimizing possible operator related bias.

Regarding validity of the results, our study population was representative of a mix of rural and urban population which is a characteristic of the city we live in with no significant differences among them.

According to baseline characteristics and the overall complication rate (5.2%) in this study is comparable to previous reports^(11,12).

However, the complication rate in the control group was found to be relatively high (10%) in comparison to low rate in the study group (4.4%).

This may be due to prolonged operation time and repeated trial of introducing the curette to check for complete evacuation what is called security checks⁽¹³⁾.

These curettage trials increased the risk of complications especially perforation and infection together with increased blood loss during and after the procedure.

In a large observational study in Sweden (n. 14,800) involving 140 recognized perforations in the first trimester, 31% occurred during the "security check"⁽¹⁴⁾. There are no data to suggest that check curettage reduces the risk of retained products or failed evacuation⁽¹⁵⁾.

However many clinicians check the completeness of the procedure by gentle sharp curettage followed by final suctioning⁽¹³⁾.

This has also been the practice in El-minia university maternity hospital where the study was settled With the use of ultrasono-

graphy it should be possible to confirm the completeness of evacuation without resorting to check curettage and avoid associated risk of uterine perforation or excessive curettage leading to Asherman syndrome⁽¹⁶⁾.

The convalescence time was longer in women who had their operation without ultrasound guidance and they were more likely to see a doctor following the operation. This may again be related to longer postoperative pain and bleeding in this group of patients.

As regard perforation which considered as a major complication during the procedure, it occurred in five cases, one in the study group and the other four cases in the control group with high significant differences (p value 0.004) this is similar to Darney and Sweet 1989, who stated that routine use of intra-operative ultrasonography during first trimester abortion has been shown to reduce the rate of uterine perforation¹⁷. Uterine perforation during suction curettage is a potentially dangerous complication but can go unrecognized on many occasions⁽¹⁸⁾. Intraoperative ultrasonography not only provides visual guidance to the surgeon to direct the instruments and minimize the risk of perforation but also provides confirmation of suspected perforation and may enable completion of the evacuation⁽¹⁹⁾.

The rate of significant haemorrhage (blood loss more than 200 ml) Was nearly equal in both groups and no patient required blood transfusion. However, measured intra-operative blood loss was significantly less in the intervention group (90±37 ml versus 100±45ml in the control group with significant difference of 0.03 p value). The amount of blood loss at D&C operation is related to the gestational age and the operative time. As the mean gestation was similar in the both groups it is possible that the reduction in blood loss was mainly due to the reduction in the procedure time.

The time required to evacuate the uterine contents was significantly shorter when ultrasound guidance was used.

This may be mainly due to reduction in time required to determine the completeness of evacuation by repeated check curettage. There was a need to repeat the operation in five cases in the control group with no cases in the study group suggestive of complete evacuation of the uterine cavity with significant p value (0.0003).

The convalescence time was longer in women who had their operation without ultrasound guidance and they were more likely to see a doctor following the operation. This may again be related to longer postoperative pain and bleeding in this group of patients.

The cost of intraoperative ultrasound scanning was not assessed in this study which expected to be cheaper if compared with possible complication which might come.

Capsi et al.,⁽¹⁴⁾ used real-time ultrasound guidance in 20 cases and ultrasound examination before and after the procedure in 10 cases of early pregnancy termination and found this to be safer than the conventional procedure.

Whether an approach of performing a scan preoperatively followed by another scan at the end of the procedure will have a similar effect in terms of outcomes needs to be further investigated.

In conclusion, this study suggest to use ultrasound guidance during blind D&C operation in the first trimester missed abortion and so could be used in any cases of blind intra- uterine manipulation to reduce the risk of perforation, bleeding and operative time.

Acknowledgment:

A lot of thanks to be given to all staff members in the department of obstetrics and gynecology faculty of medicine, Minia university, in supporting us during this work.

References

1. Uterine Bleeding. In: Emons SJ. Pediatric and Adolescent Dysfunctional

- Gynecology. 6th ed. Philadelphia: Lippincott Williams & Wilkins; 2004.
2. McElin TW, Bird CC, Reeves BD and Scott RC. Diagnostic dilatation and curettage. A 20-year survey. *Obs. Gynecol.* 1969; 33(6):807-12.
 3. Stovall TG, Solomon SK and Ling FW. Endometrial sampling prior to hysterectomy. *Obstet Gynecol.* 1989; 73(Pt 1):400-9.
 4. Boardman LA, Mainz H, Steinhoff MM, Heber WW and Blume J. A randomized trial of the sleeved cytobrush and the endocervical curette. *Obstet Gynecol.* 2003; 101(3):426-30.
 5. MacKenzie IZ and Bibby JG. Critical assessment of dilatation and curettage in 1029 women. *Lancet.* 1978; 2(8089):676-8.
 6. Christianson MS, Barker MA, Lindheim SR. Overcoming the challenging cervix: techniques to access the uterine cavity. *J Low Genit Tract Dis.* Jan 2008; 12(1):24-31
 7. Criniti A and Lin PC. Applications of intraoperative ultrasound in gynecological surgery. *Curr Opin Obstet Gynecol.* 2005; 17:339-342.
 8. Mitwally MF, Albuarki H, Diamond MP, et al. Gestational sac aspiration: a novel alternative to dilation and evacuation for management of early pregnancy failure. *J Minim Invasive Gynecol.* 2006; 13:296-301.
 9. Word B, Gravlee LC, Wideman GL. The fallacy of simple uterine curettage. *Obstet Gynecol.* Dec 1908; 12(6):742-8.
 10. Egyptian ministry of health, maternal mortality report, 2008.
 11. Heisterberg L and Kringelbach M. Early complications after induced first trimester abortion. *Acta Obstet Gynecol Scand.* 1987; 66:201-4.
 12. Joint Study of the Royal College of General Practitioners and the Royal College of Obstetricians and Gynaecologists. Induced abortion operations and their early sequelae. *Journal of the Royal College of General Practitioners.* 1980; 30:170-180.
 13. Acharyaa G, Morgana H, Paramanathama L and Fernando R. A randomized controlled trial comparing surgical

- termination of pregnancy with and without continuous ultrasound guidance. *European Journal of Obstetrics & Gynecology and Reproductive Biology*. 2004;(114):79-84
14. Capsi B, Appelman Z, Manor Y, Barash A, Eliraz A and Insler V. Early pregnancy termination: an improved technique for "menstrual regulation" with ultrasound assistance. *Adv Contracept*. 1992;8:349-53.
15. Lindell G and Flam F. Management of uterine perforation in connection with legal abortions. *Acta Obstet Gynecol Scand*. 1990;74:373-5.
16. Lichtenberg ES, Grimes DA and Paul M. Abortion complications: prevention and management. In: Paul M, Lichtenberg ES, Borgatta L, Grimes D, Stubblefield PG, editors. *A clinician's guide to medical and surgical abortion*. New York: Churchill Livingstone; 1999;197-216.
17. Towbin NA, Gviazada IM and March CM. Office hysteroscopy versus ultrasound in the evaluation of patients with excessive uterine bleeding. *Am J Obstet Gynecol*. 1996;174:1678-1682.
18. Darney PD and Sweet RL. Routine intra-operative ultrasonography for second trimester abortion reduces incidence of uterine perforation. *J Ultrasound Med*. 1989;8:71-5.
19. Lajinian S, Margono F and Mroueh J. Sonographic appearance of suspected iatrogenic uterine perforation: a case report. *J Reprod Med*. 1994;39:911-2.
20. Kohlenberg CF and Casper GR. The use of intraoperative ultrasound in the management of a perforated uterus with retained products of conception. *Aust NZ J Obstet Gynaecol*. 1996;36:482-5.